



PATIENT

Max Clapp

SPECIES

Canine

BREED

Brussels Griffon Mix

SEX

Male Neutered

AGE

13 years

WEIGHT

16.69lbs

INTERPRETED BY

Maggie Machen Lamy, DVM DACVIM (Cardiology)

IMAGING PERFORMED BY

Pamela Harrigan, RDCS

HOSPITAL NAME

Mass Veterinary Services

REFERRING VET

Dr. Masloski

INVOICE

23012

DATE

3/9/22

PRESENTING CLINICAL SIGNS

History: Max referred for heart murmur. He is doing well with only an occasional cough. Good appetite and normal activity. History of grain-free diet - not currently. On auscultation: NSR, grade III/VI murmur with PMI left apical area, PSS, lung fields clear. BP: 140mmHg x 2. -Current medications: 1) Pimobendan/vetmedin 1.25mg 1 tab twice a day 2) Gabapentin 100mg 1/2 tab twice a day *No sedation for study.

ECHOCARDIOGRAM FINDINGS

2D, m-mode, color flow and Doppler imaging is available.

Left ventricle: The LV diameter is normal with adequate myocardial function. LV wall thicknesses are normal.

Left atrium: The left atrium is mildly dilated.

Mitral valve: The mitral valve is diffusely thickened with minimal prolapse into the left atrial lumen. Mild to moderate eccentric mitral regurgitation with a normal velocity.

Aortic valve/aorta: The aortic valve is normal in morphology and mobility. Trace aortic outflow velocity; laminar flow. No aortic insufficiency.

Right ventricle: Normal right ventricular diameter and morphology indicating no overt evidence of pulmonary arterial hypertension.

Right atrium: Normal RA dimension.

Tricuspid valve: The tricuspid valve appears normal with trace tricuspid regurgitation; normal velocity.

Pulmonic valve/pulmonary artery: The pulmonic valve is normal in morphology and mobility. No pulmonic insufficiency. Normal RVOT velocity; laminar flow.

Pericardium/other: No pericardial or pleural effusion noted. No obvious cardiac masses.

Heart rhythm: ECG reveals a sinus rhythm with an average HR of 130bpm.

2-Dimensional Measurements

Ao diam (cm)	1.6
LA diam (cm)	2.4
LA:Ao (Swe)	1.5
IVS thickness (cm)	0.75
LVID diastole (cm)	2.6
PW thickness (cm)	0.75
LVID systole (cm)	1.1
FS (%)	58

Doppler Measurements

PV Vmax (m/s)	1.75
AoV Vmax (m/s)	1.5
MR Vmax (m/s)	5.7
TR Vmax (m/s)	2.5
TR PG (mmHg)	25

INTERPRETATION OF THE FINDINGS

The cause of the murmur is chronic degenerative valve disease causing mild mitral and trace tricuspid regurgitation. Lack of significant left atrial enlargement indicates the current risk for complication is low. A small aortic leak is noted; however, blood pressures are normal. No concurrent issues such as pulmonary hypertension are noted in this study.

No medications are indicated and Pimobendan can be safely discontinued. Assessment of progression in the future will help predict long term prognosis, which is highly variable at this stage (B1).

RECOMMENDATIONS

- In a dog without significant left atrial enlargement, no cardiac medications are clearly indicated and discontinue Pimobendan as discussed.



PATIENT

Max Clapp

SPECIES

Canine

BREED

Brussels Griffon Mix

SEX

Male Neutered

AGE

13 years

WEIGHT

16.69lbs

INTERPRETED BY

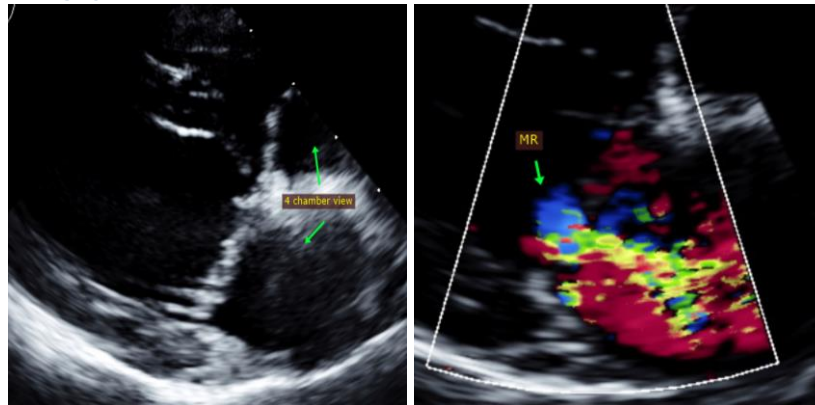
Maggie Machen
Lamy, DVM
DACVIM (Cardiology)

- Omega fatty acid supplementation and mild salt restriction may be of some long-term benefit.
- Anesthetic risk is considered mild if needed. Cardiac protective drug choices (opioid/benzodiazepine premedication, propofol or alfaxalone induction, isoflurane gas) are recommended. Pre-oxygenate for 5-10 minutes prior to induction. Monitor for arrhythmias, hypotension, and hypoxia both intra and post-operatively and intervene as necessary. Mild IV fluid restriction is recommended to avoid fluid overload. Avoid heart rate stimulating drugs such as atropine unless clinically indicated.
- Monitor for development of a cough, labored breathing, exercise intolerance or collapse episodes.

PLAN

- Recommend conservative monitoring with a recheck echocardiogram in 6 months, sooner if any development of clinical signs.

IMAGES



IMAGING PERFORMED BY

Pamela Harrigan,
RDCS

The information and recommendations provided are based on the images presented by the referring veterinarian. No evaluation can be communicated regarding pathology that was not visible in the image/video clips provided.

HOSPITAL NAME

Mass Veterinary
Services

Thank you for this referral. This report was generated using transcription software, and minor dictation errors may be present. If the clinical or image interpretation does not parallel your findings or if I can be of any further assistance, please contact me.

REFERRING VET

Dr. Masloski

Maggie Machen Lamy, DVM
Diplomate of the American College of Veterinary Internal Medicine (Cardiology)
info@sonopath.com

Echocardiogram performed by:

Pamela Harrigan, RDCS
Pet Animal Ultrasound Service (4paus.com)

INVOICE

23012

DATE

3/9/22